Retard ventriculaire droit : exemples de morphologies d'ECG

Exemple 1

Avant administration de bolus de bicarbonate de sodium

Après administration de bolus de bicarbonate de sodium

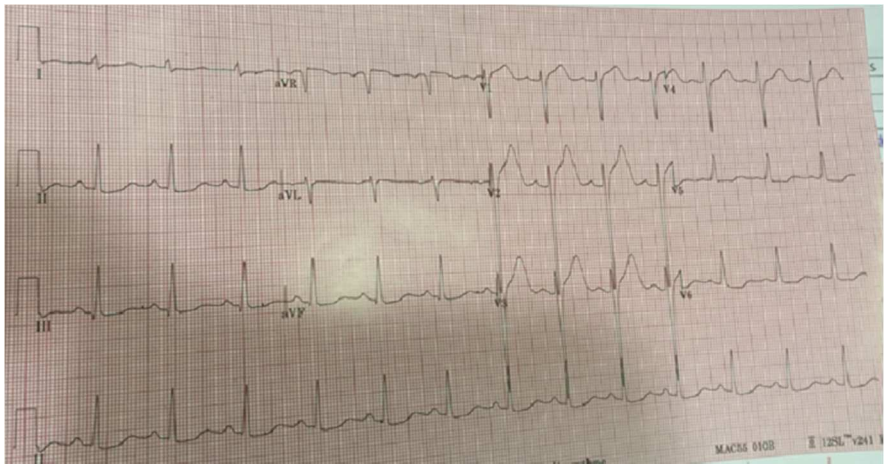

Exemple 2

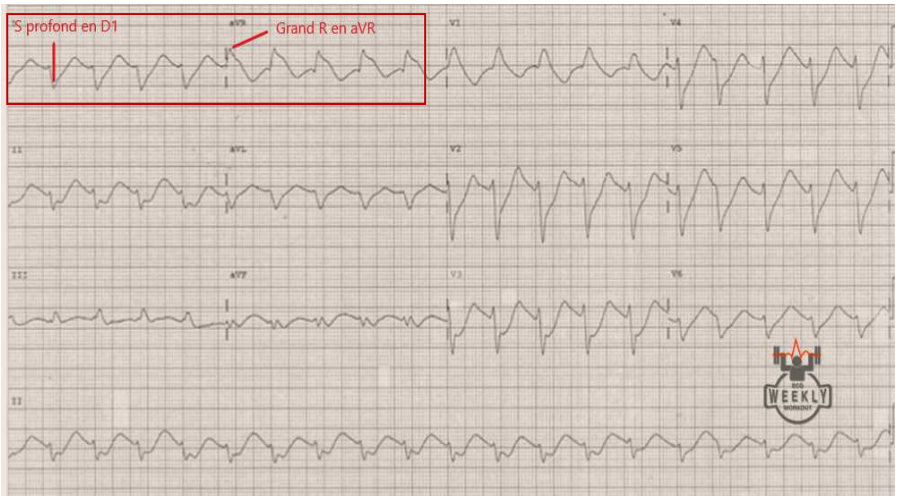

Exemple 3

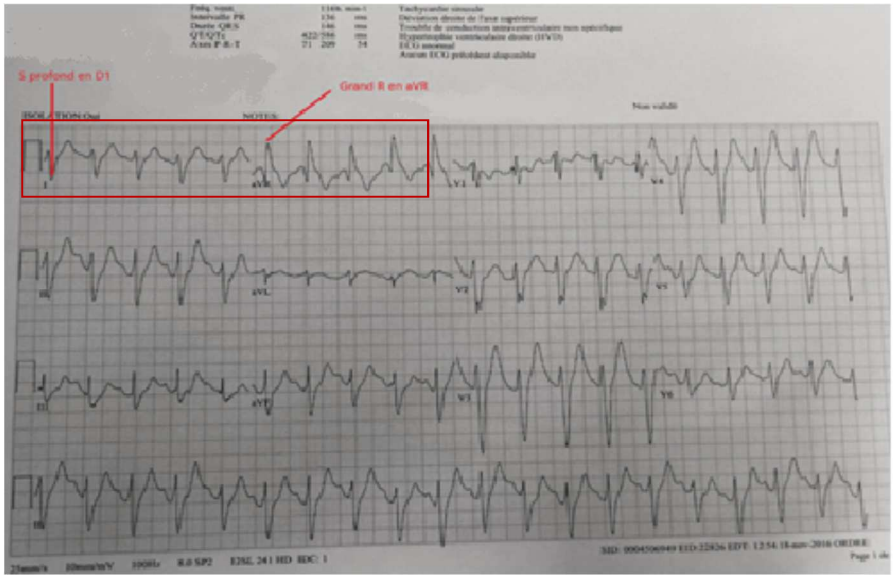

Exemple 4

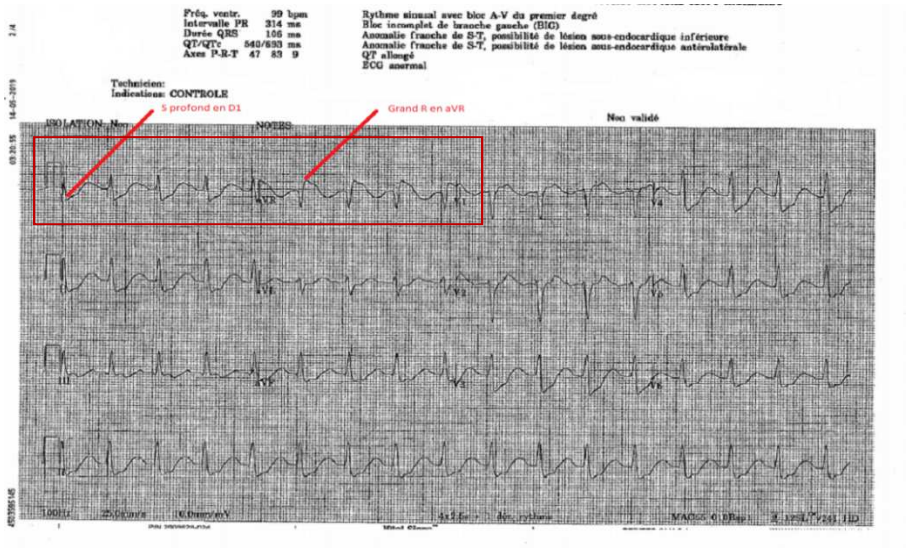

Exemple 5

Avant administration de bolus de bicarbonate de sodium

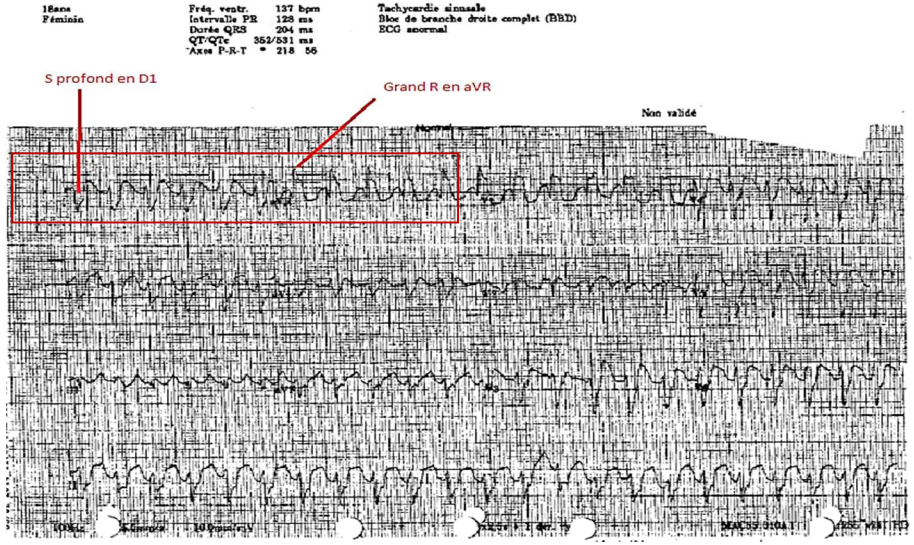

Après administration de bolus de bicarbonate de sodium

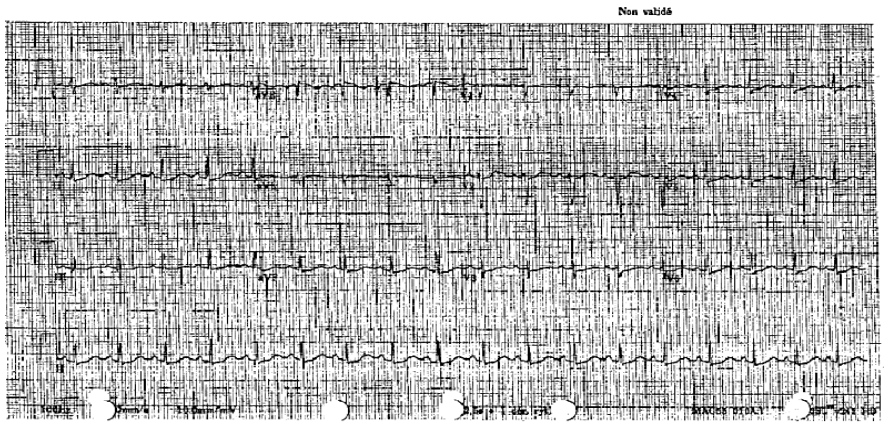

Exemple 6

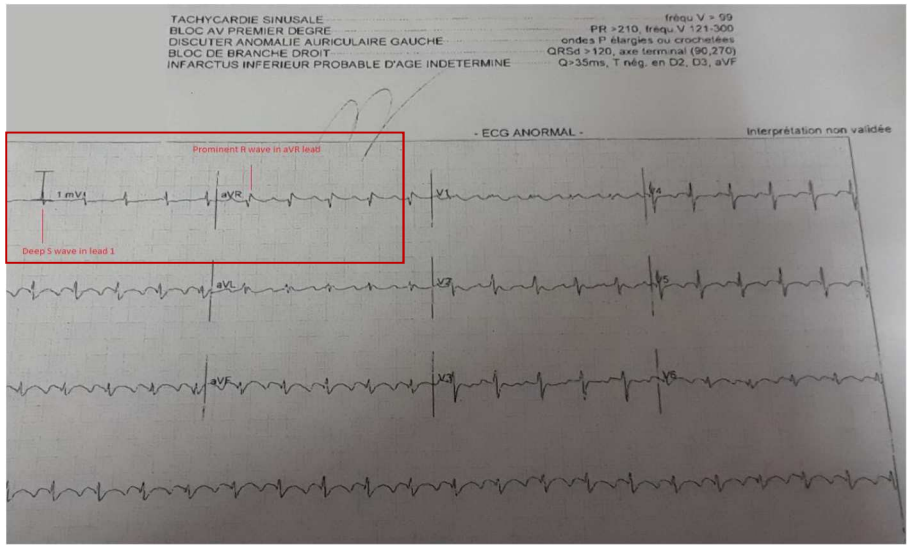

Exemple 7

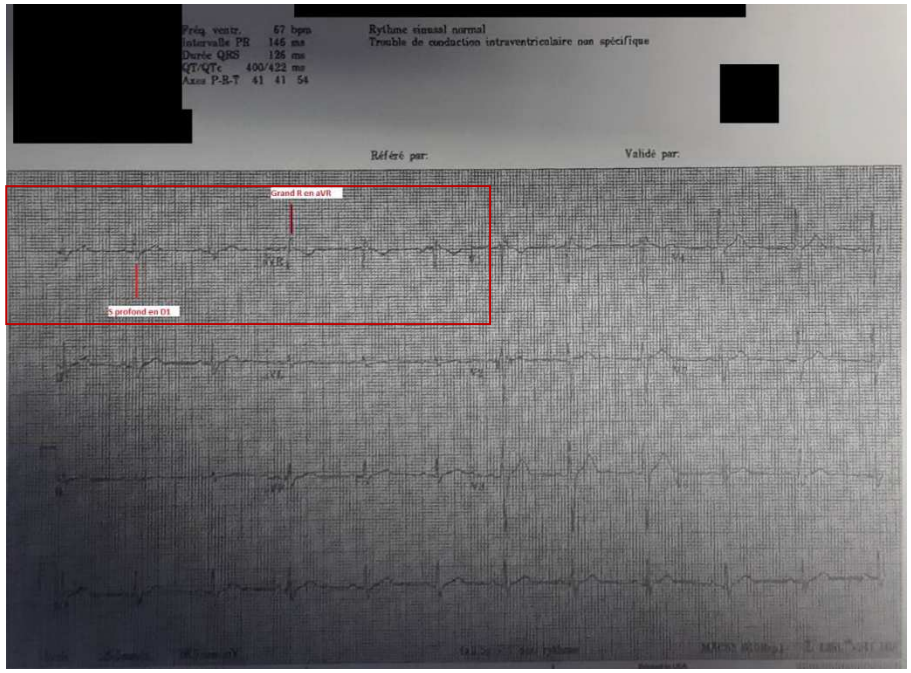
Fréq. ventr. 67 bpm
Intervalle PR 146 ms
Durée QRS 126 ms
QT/QTc 400/422 ms
Axes P-R-T 41 41 54
Rythme sinusal normal
Trouble de conduction intraventriculaire non spécifique
Référé par:
Validé par:
Grand R en aVR
S profond en D1